

# Inner Scar Umbilicus: New Horizons for Vertical Abdominoplasty

Flavio H. Mendes, M.D.,  
Ph.D.

Fausto Viterbo, M.D., Ph.D.

Ana L. A. P. Luna, M.D.

São Paulo, Brazil



**Background:** It is reasonable that deflated tissue in massive weight loss patients may demand not only lifting but also some extent of central body tightening, by the fleur-de-lis procedure. Although achieving nice contouring results, poor visible scars, including umbilical complications, have restricted the indications for the anterior vertical approach. The purpose of this article is to present the authors' experience with the inner scar umbilical reconstruction, reflecting overall results in vertical abdominoplasties.

**Methods:** Massive weight loss patients who underwent fleur-de-lis abdominoplasties with the inner scar umbilicus were reviewed retrospectively. The original stalk was resected along with the surgical specimen, and two marked parallel skin flaps were kept and sutured against each other into the deep medial fascia, to reconstruct the umbilical base. Additional sutures were made to approximate fat tissue immediately under and above it, enhancing a deepening effect. Conventional upper and lower vertical closure helped to establish the tridimensional shape of the new navel.

**Results:** One hundred ten consecutive patients were studied, and 52 (47 percent) presented small inflammatory exudate arising from the inner suture, which resolved with conservative dry dressings. No further umbilical complications such as infection, necrosis, dehiscence, widening, or stenosis were reported, and all patients showed natural and scarless new navels with nice shapes and correct position.

**Conclusions:** The inner scar umbilicus is a simple, safe, and reproducible technique, presenting low complication rates with sustainable and natural results. High-quality navel reconstruction favors the indication of vertical abdominoplasties, especially for post-bariatric surgery body contouring. (*Plast. Reconstr. Surg.* 141: 507e, 2018.)

**CLINICAL QUESTION/LEVEL OF EVIDENCE:** Therapeutic, IV.

**R**ebuilding umbilical architecture following abdominoplasty is considered one of the most challenging tasks, especially for massive weight loss patients, who usually present with elongated umbilical stalks and critical tissue excess in both vertical and horizontal planes. Although anterior vertical resections may provide enhanced lower body contouring for that population, such

indications have been restricted by visible and pathologic scarring, usually with stigmatizing umbilical distortions. The presence of an “outer scar” around the umbilicus has been recognized as a source of several surgical complications that may lead to undesirable scarring with anatomical

*From the Division of Plastic Surgery, Botucatu Medical School–Paulista State University (Universidade Estadual Paulista).*

*Received for publication May 25, 2017; accepted September 15, 2017.*

*Presented at the Abstracts Session of the Aesthetica Super Symposium (American Society of Plastic Surgeons) 2017, in New Orleans, Louisiana, March 2 through 4, 2017, and Selected as Best Abstract presented at the Symposium and Winner of the Aesthetica Scholarship 2017 Award.*

*Copyright © 2018 by the American Society of Plastic Surgeons*

DOI: 10.1097/PRS.0000000000004258

**Disclosure:** *The authors have no financial interest to declare in relation to the content of this article. No funding was received for this article.*

Supplemental digital content is available for this article. Direct URL citations appear in the text; simply type the URL address into any Web browser to access this content. Clickable links to the material are provided in the HTML text of this article on the *Journal's* website ([www.PRSJournal.com](http://www.PRSJournal.com)).

disarrangement and poor aesthetic results, ultimately resulting in stenosis or widening of the navel.<sup>1</sup>

After the introduction of a “double lateral skin flap” to reconstruct the umbilicus within an anterior vertical scar,<sup>2</sup> several authors have also suggested similar approaches for creating a new umbilicus during the fleur-de-lis abdominoplasty.<sup>3–8</sup> Donnabella<sup>8</sup> popularized such a concept, stating the importance of recreating all of the umbilical anatomical landmarks (i.e., base, grooving, and ring) in search of natural results. Although conceptually comprehensive, those publications lack standardization and full description of the technical steps. Following Donnabella’s principles, we have suggested a specific and reproducible looping suture technique to anatomically recreate the new umbilicus.

## PATIENTS AND METHODS

Medical records of massive weight loss patients who underwent fleur-de-lis abdominoplasty from January of 2013 until December of 2015 were retrospectively reviewed. Selection criteria included patients of both sexes who underwent the inner scar umbilicus procedure following vertical abdominoplasty, with or without associated circumferential resection. All patients had a maximum body mass index of 30 kg/m<sup>2</sup> and presented weight stabilization, which is defined in our service by a variation less than 3 percent of the initial weight within a 3-month period, beginning at least 18 months after bariatric surgery.<sup>9</sup> Patients received all of the information regarding medical procedures, including aesthetic possibilities and limitations of the results, extensively described within the informed consent terms. During both surgical and data review phases, this study was conducted in accordance with the human studies guidelines at the Botucatu Medical School of the Paulista State University (UNESP), under the principles of the Declaration of Helsinki.

### Markings

Both vertical markings of the anterior resection included the design of a lateral skin flap, 8.0 × 1.5 cm, that would be undermined and preserved by its pedicle, apart from the resected surgical specimen. We prefer to mark those lateral skin flaps initially wider than they will finally stand, to allow a greater range of possibilities for better establishing the umbilical final position, after moving and approximating remaining abdominal tissue.<sup>3</sup>

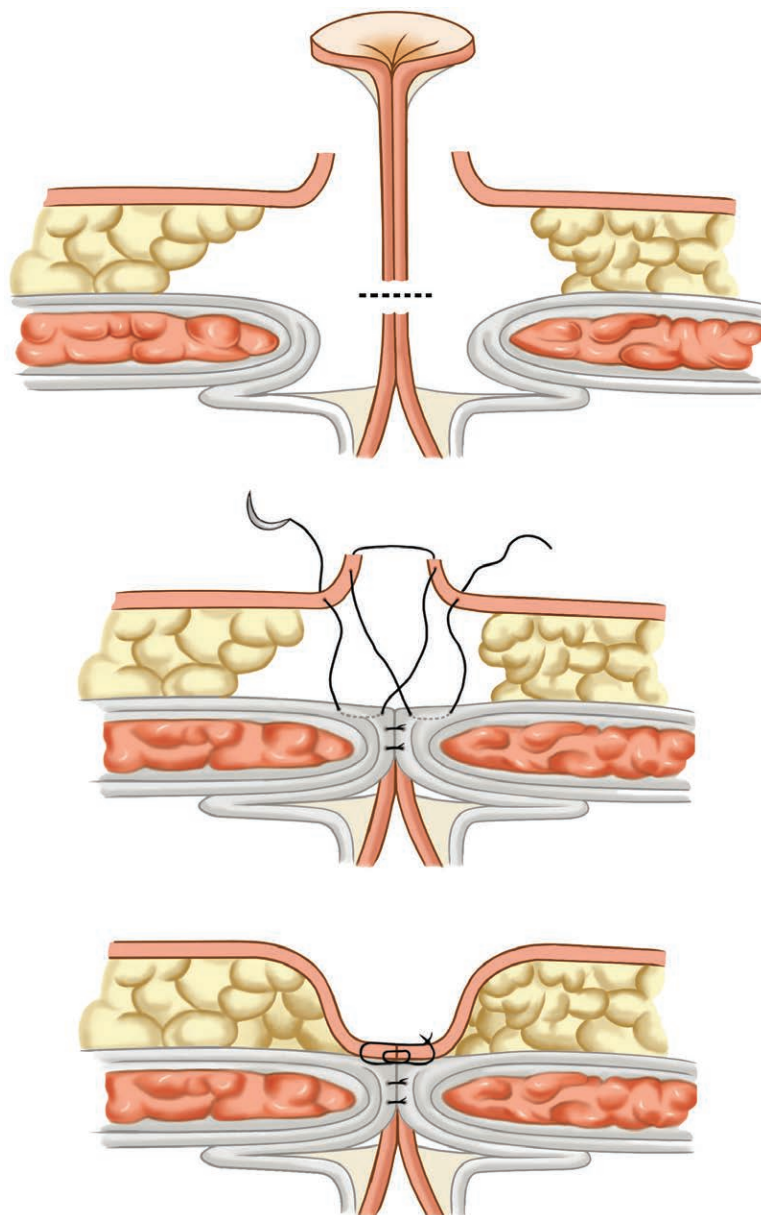
### Technique

In supine position, we started the abdominal undermining through the inferior horizontal incision facing upward until the umbilical level. After complete skin incision of the right vertical limb and flap elevation on both sides, cautery dissection was performed all the way through the subcutaneous tissue until the rectus sheath dissection plane. The same procedure on the left side joined both dissections at the vertical midline. During anterior tissue detachment, patients had the umbilical stalk isolated, clamped, and cut at its base, being finally resected along with the surgical specimen. A continuous closure suture with 2-0 nylon was performed at the base just adjacent to the rectus sheath. Aponeurosis plication was performed as usual, whenever necessary. While suturing the vertical edges, both parallel skin flaps (8.0 × 1.5 cm) that were preserved by the fleur-de-lis preoperative demarcation were then intraoperatively redesigned into a proper size and position, at the iliac crest level, finally measuring approximately 2.5 × 1.5 cm. Rather than being rectangular with sharp edges, the final shape of the flaps had a rounded design.<sup>8</sup> After removing excessive tissue and defatting the skin flaps, three nylon 3-0 sutures were placed in a looping technique to create a medial deep aponeurotic attachment, reconstructing the navel base.

### Umbilical Base: Looping Suture

First, the looping suture needle initially enters the skin and transects the left flap exiting through the dermis, at 1.0 cm far from its edge. Second, it now enters the rectus sheath at the same side and runs immediately under it for 1.0 cm until exiting at the midline. Then, the suture needle grasps 0.5 cm of the contralateral flap dermis exiting on its edge to perform the same 0.5-cm grasping on the left side, entering at its edge and exiting inside the dermal aspect of the flap. Next, the needle reenters the rectus sheath at the midline and runs immediately under it for 1.0 cm until exiting at the right side. Finally, the needle transects the right flap entering the dermis and exiting through the skin, at 1.0 cm far from its edge. Figure 1 shows a drawing sequence of the umbilical base reconstruction by the lateral skin flaps.

Three looping sutures were performed as mentioned above, one at the center and two others at the superior and inferior borders of the flaps. Initial stitches were left loose to facilitate the accomplishment of the following ones, and they were all tightened at the end. Tightening



**Fig. 1.** Illustration of the operative sequence of the looping suture to reconstruct the umbilical base.

of each looping suture helped to squeeze the flaps against each other into the deep midline aponeurosis.

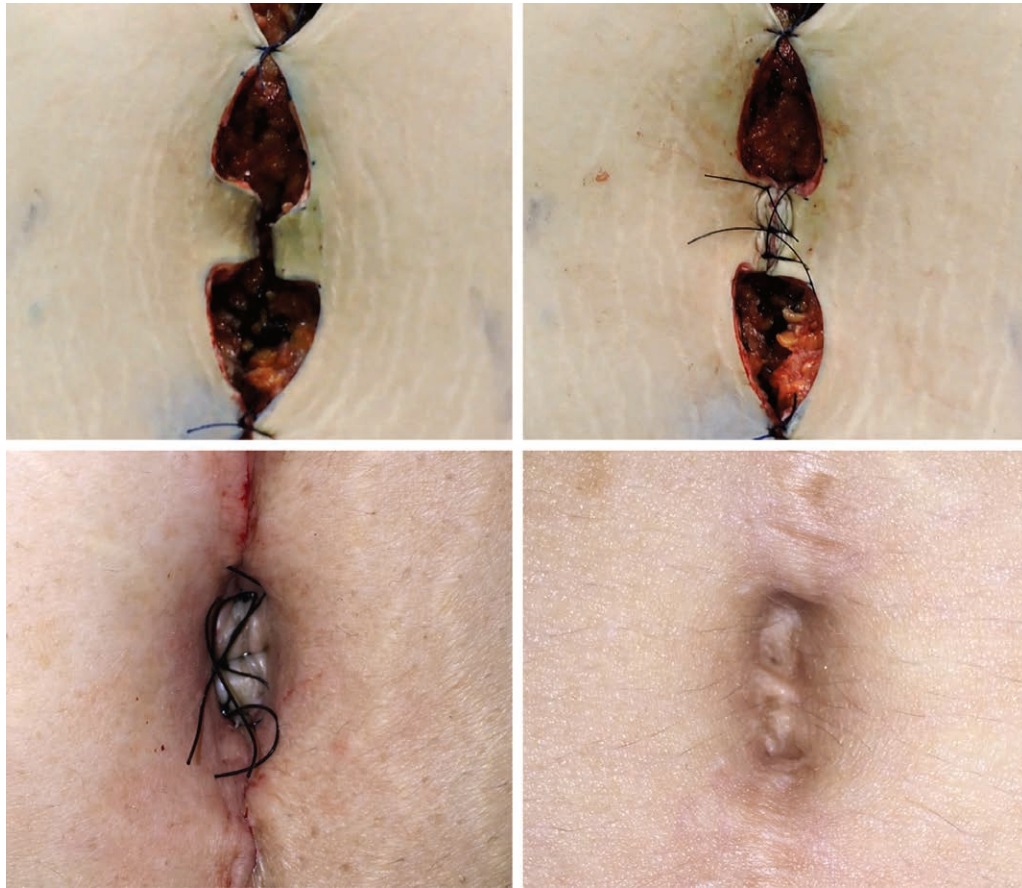
#### **Umbilical Grooving: Fat Suture**

Because it is not possible to retract the umbilical base deeper than the aponeurosis level, the best umbilical grooving was achieved by increasing the projection of the surrounding areas. That was accomplished by two 2-0 Vicryl sutures (Ethicon, Inc., Somerville, N.J.), with a long needle (4 cm), approximating lateral fat tissue into the midline right above and immediately under the reconstructed umbilical base.

#### **Umbilical Ring**

After reconstructing the base and establishing proper navel grooving, the three-plane suture of the vertical edges helped to provide the ring configuration of the umbilicus, as it approximates the covering tissue under and above the new navel. After all, deep cutaneous attachment to the rectus sheath (base), surrounded by normal subcutaneous tissue (grooving) and scarless outer skin configures the natural ring appearance to the surface of the abdominal wall around the umbilicus.

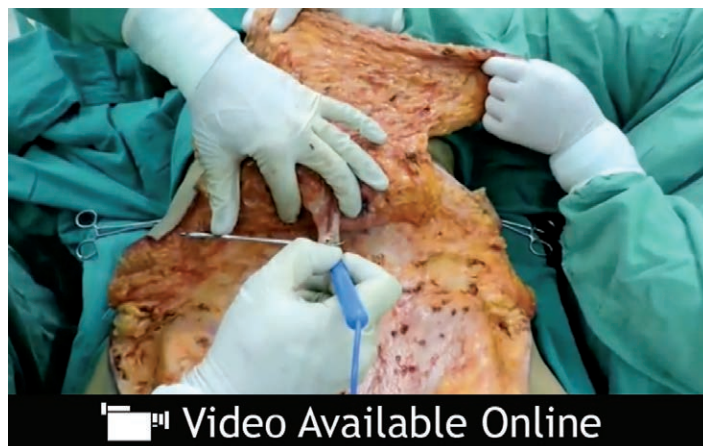Figure 2 shows a sequence of the intraoperative and postoperative flap constitution, and



**Fig. 2.** Sequence of the inner scar umbilicus technique with immediate and late results.

a video demonstrates the surgical details of the inner scar umbilicus technique. (See **Video, Supplemental Digital Content 1**, which demonstrates technical details on designing, creating, and

suturing two lateral skin flaps for reconstructing the navel in a vertical abdominoplasty, available in the “Related Videos” section of the full-text article on PRSJJournal.com or, for Ovid users,



**Video.** Supplemental Digital Content 1 demonstrates technical details on designing, creating, and suturing two lateral skin flaps for reconstructing the navel in a vertical abdominoplasty, available in the “Related Videos” section of the full-text article on PRSJJournal.com or, for Ovid users, available at <http://links.lww.com/PRS/C677>.

available at <http://links.lww.com/PRS/C677>.) The looping stitches were kept in place to be completely removed after 30 days, whereas the vertical incisions had absorbable internal sutures. All patients were assessed retrospectively for the occurrence of umbilical complications and their consequences, by reviewing medical records. The quality of the results was established by the observation of 12-month postoperative photographs and a subjective classification, by the first author, regarding umbilical position, shape, and overall contour appearance.

## RESULTS

One hundred ten consecutive massive weight loss patients were included in this study, as all of them underwent vertical abdominoplasty with the inner scar umbilicus procedure. Seventy-five patients (68 percent) underwent the sole classic fleur-de-lis operation, whereas 35 patients (32 percent) underwent the anterior procedure associated with circumferential tissue resection (belt lipectomy). Also regarding the umbilical approach, all patients were marked and operated on by the same technique, under direct assistance of the first author (F.H.M.). A great majority of the cases ( $n = 98$  (89 percent)) were women, and 12 were men (11 percent). Intravenous general anesthesia was performed in 51 cases (46 percent), spine blocks were performed in 38 patients (35 percent), and the association of both techniques was used in 21 patients (19 percent). Aspiration drains were applied in all cases, which remained in place for 5 to 10 days, until daily debit dropped below 40 ml. Prophylactic antibiotics were initiated intravenously in the operating room (30 minutes before the incision) and maintained orally for several days after hospital discharge, which took place between 18 and 36 hours after surgery.

The most frequently reported complication postoperatively was the occurrence of small spots of dehiscence along the suture lines [24 cases (22 percent)], all of which were treated conservatively by local wound dressings. Seromas were also reported in 19 cases (17 percent), being treated by serial needle aspirations or natural drainage and local dressings. Two patients (1.8 percent) presented with expansive hematomas requiring surgical reintervention in the immediate postoperative period. In the present series, there were no reported cases of infection, skin necrosis, or thromboembolic events. Vertical scars located above and under the new umbilicus were

considered to have favorable evolution without pathologic behavior.

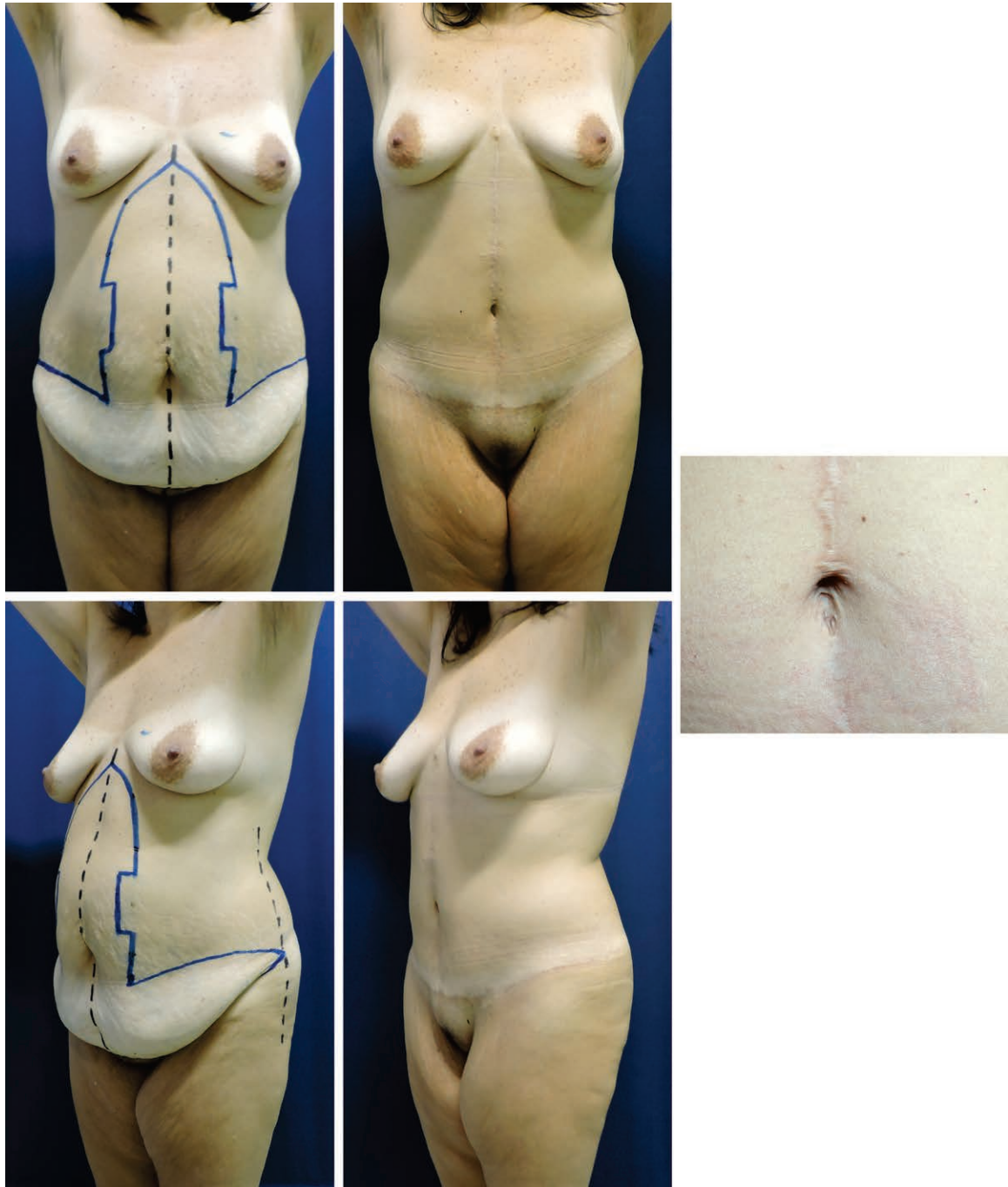
Regarding local umbilical adverse events, 52 patients (47 percent) presented with mild inflammation and some exudate arising from the new umbilicus during the initial 15 to 20 days. All of them showed total clinical resolution with conservative treatment by means of open and dry dressings. No further umbilical complications were reported, such as infection, necrosis, dehiscence, widening, or stenosis, and all patients showed natural and scarless new navels with nice shapes and proper position.

The method led to unquestionable body contouring enhancement for all patients, with low complication rates, and the inner scar umbilicus helped to provide safe, natural, and sustainable results. Figures 3 through 5 show the contouring outcomes of different massive weight loss patients treated by vertical abdominoplasty and the proposed umbilical procedure, with or without circumferential lipectomy.

## DISCUSSION

Normal umbilical appearance is fundamental for achieving harmonious body contouring with aesthetically balanced abdominal results. The navel has been stated as the “surgeon’s signature” and must receive appropriate attention during the approach, as no surgical outcome will be considered completely favorable if it presents with problems regarding shape, size, position, and scarring.<sup>10-14</sup> One important concept while managing the umbilicus is to keep in mind its anatomical landmarks, which include the base (a portion of abdominal skin closely attached to the rectus sheath), the grooving (circular skin wall between the deep base and superficial abdominal tissue), and the ring (rounded aspect of the abdominal skin that reflects into the grooving). It is interesting to note that most individuals present several different umbilical shapes, but all of them may be considered normal, provided that those landmarks are well defined. After birth, a central skin retraction is responsible to create the umbilical anatomy, and the most natural surgical reconstruction will be achieved by procedures that best reproduce that same healing pathway.

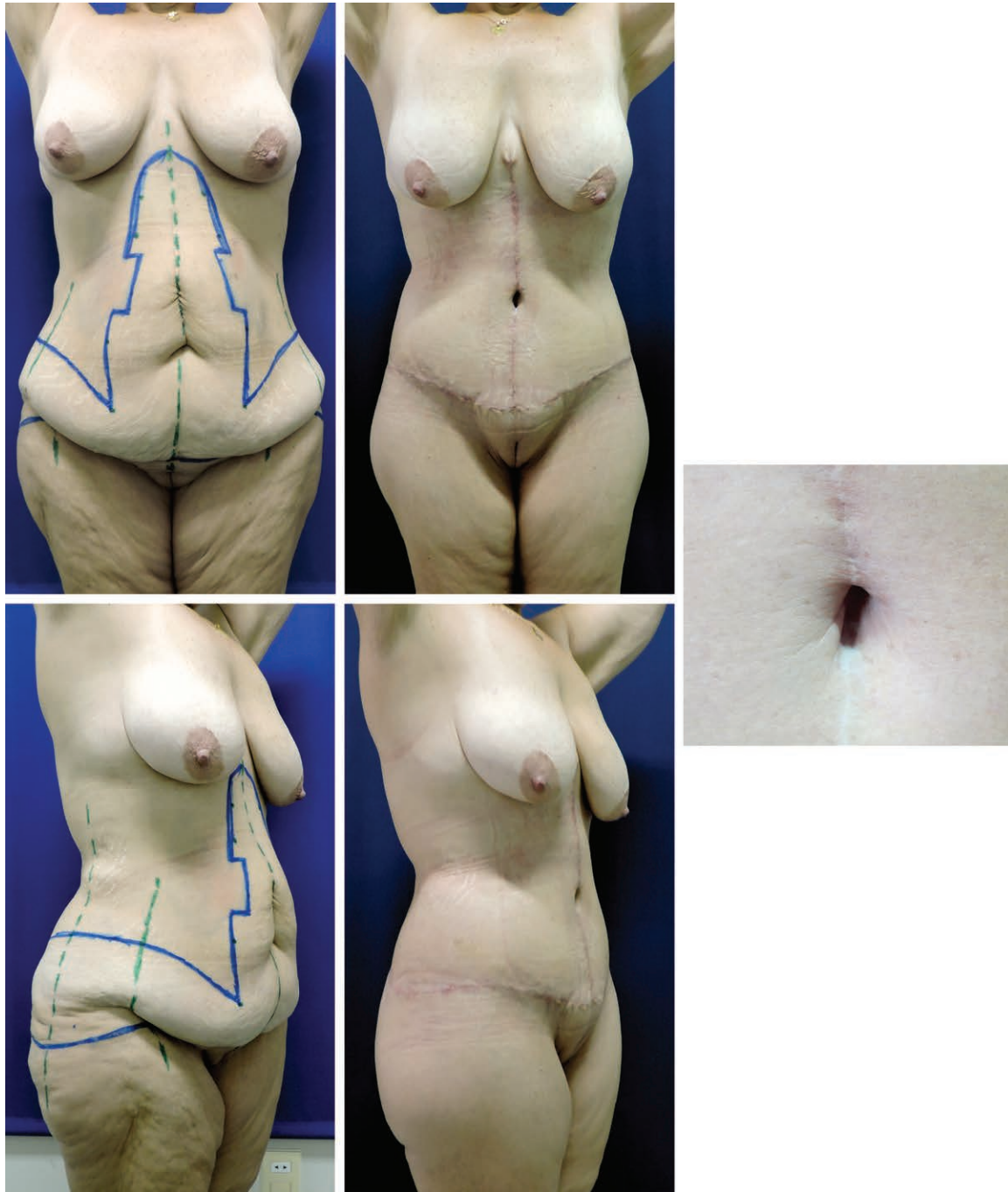In recent decades, several authors have recognized the hazards of outer umbilical scars in regular abdominoplasty, suggesting the complete amputation of the original stalk followed by different neoumbilicoplasty techniques, promoting some type of abdominal skin retraction into the



**Fig. 3.** Post-bariatric surgery patient who lost 45 kg, aged 42 years, with a body mass index of 27 kg/m<sup>2</sup>, who underwent a fleur-de-lis procedure. (Left) Preoperatively. (Center and right) Twelve months postoperatively.

deep rectus sheath.<sup>15-19</sup> In regular outer scar techniques, the incidence of necrosis, infection, and poor scarring may cause important distortions, ultimately with umbilical widening or stenosis, both of which are conditions that are very difficult to correct. Massive weight loss patients usually have long umbilical stalks, whose aponeurotic fixation ends up bulky and with which it is much more difficult to promote deep skin retraction.

Shortening of the umbilical pedicle has been described but usually leads to reduced skin area with poor scarring and subsequent umbilical stenosis.<sup>20</sup> In addition, such large tissue resections, usually required for body contouring in those patients, may produce intense traction vectors that might affect outer umbilical scars, leading to shape distortion. Especially for post-bariatric surgery patients, when vertical abdominoplasty is

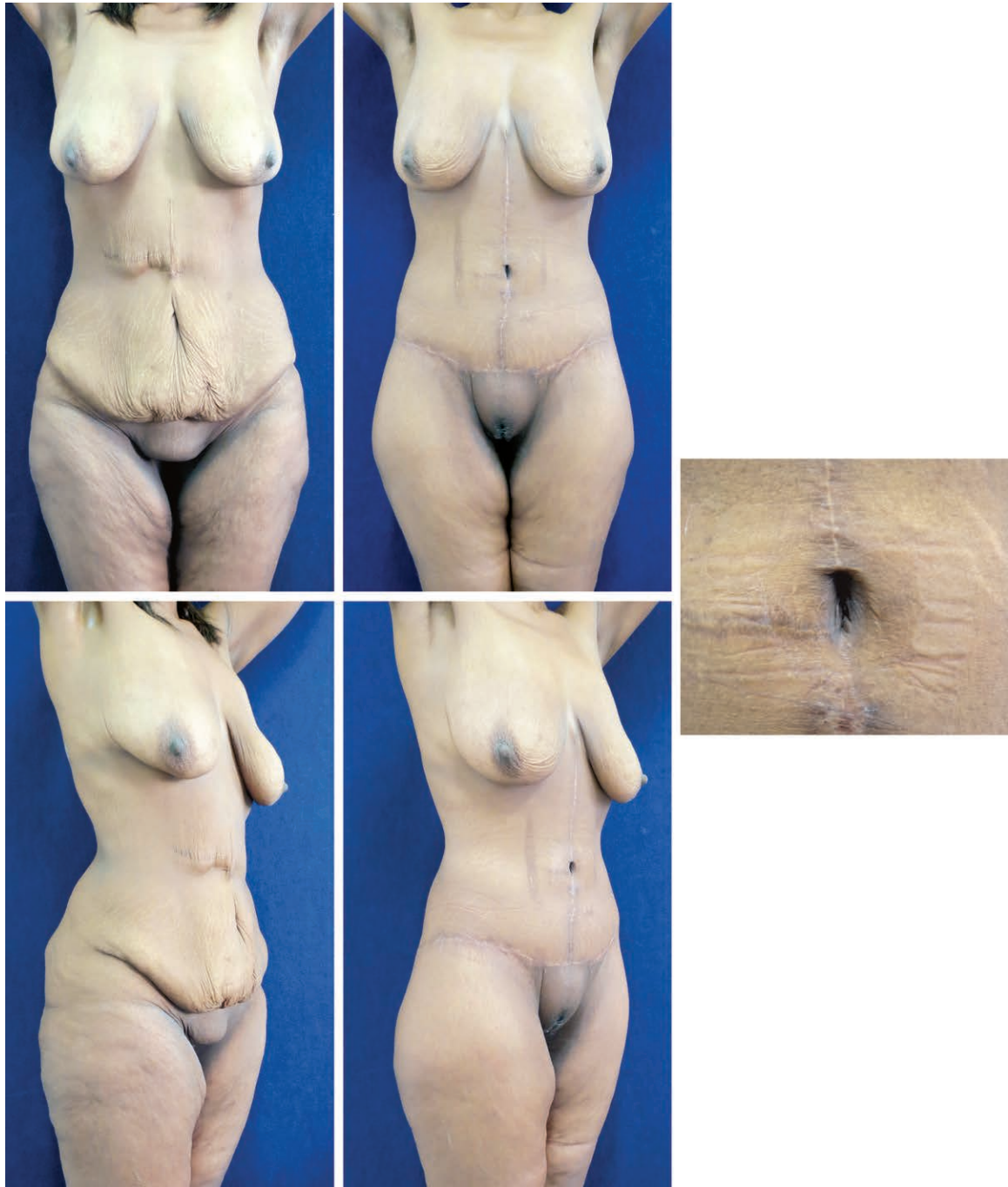

**Fig. 4.** Post-bariatric surgery patient who lost 52 kg, aged 54 years, with a body mass index of 28 kg/m<sup>2</sup>, who underwent a fleur-de-lis plus circumferential procedure. (Left) Preoperatively. (Center and right) Six months postoperatively.

indicated, preserving the original umbilicus may predispose to those drawbacks of the outer scar techniques.<sup>20</sup>

After the introduction of double lateral skin flaps to reconstruct the umbilicus within an anterior vertical scar,<sup>2</sup> there have been several publications reporting application of the technique to fleur-de-lis abdominoplasties.<sup>3-8</sup> We started our

experience in 2011, based on the description of a 20-patient series published by Silva and Oliveira.<sup>3</sup> The great contribution of those authors included the design of two initially wider lateral flaps to allow a safe and most accurate marking of the new umbilicus during the vertical suture, to match the original position established by the amputation site. We discovered that this maneuver is



**Fig. 5.** Post-bariatric surgery patient who lost 50 kg, aged 38 years, with a body mass index of 27 kg/m<sup>2</sup>, who underwent a fleur-de-lis plus circumferential procedure. (*Left*) Preoperatively. (*Center and right*) Eighteen months postoperatively.

especially useful for beginners (as the preoperative markings might not be as accurate for exactly predicting the ideal location of the new umbilicus) and in patients with intense deflation and tissue laxity. With time, we also figured out that the original amputation site was not necessarily the best level for placing the new umbilicus, and that an important decision should be made after

removing excessive tissue and closing both vertical and horizontal sutures. To achieve the most natural and anatomical navel positioning, one must consider the new overall lower body shape in relation to the iliac crest position, and that sometimes may suggest the marking of the final umbilical flaps a little higher or even a little lower than the original stalk level. Preoperatively designing

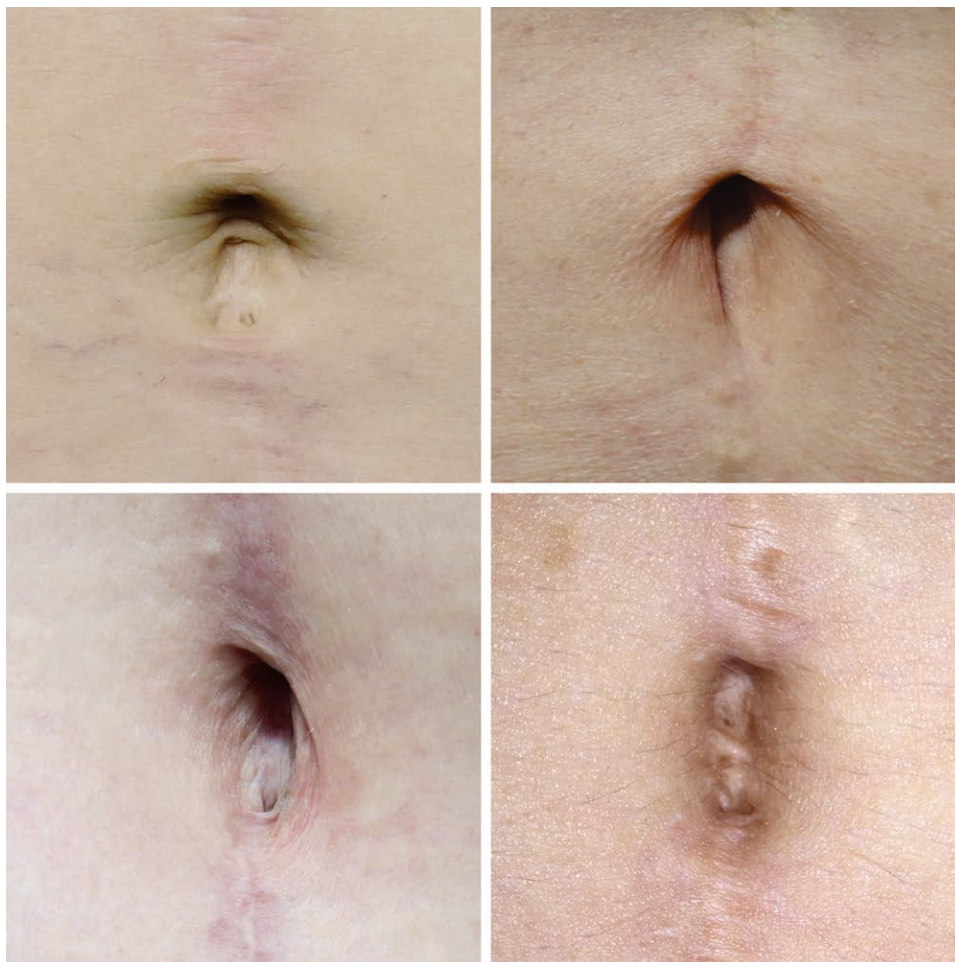

the lateral flaps wider makes it possible to have a safer and more reliable opportunity for intraoperatively marking and placing the new umbilicus in the best position, improving aesthetics and avoiding misplacement. The final size of the umbilical skin flaps could vary from  $2.0 \times 1.5$  cm to  $2.5 \times 2.0$  cm, depending on the patient's trunk biotype and the abdominal subcutaneous thickness. Another important technical point is to completely remove the subcutaneous fat tissue under the umbilical skin flaps to accomplish adequate base retraction into deep aponeurosis.

In the beginning of our inner scar umbilicoplasty experience, we performed simple external suturing of the lateral skin flaps to the midline deep fascia, following descriptions available at the time.<sup>2,3</sup> That resulted in us having many cases where the postoperative results appeared like a small vertical "sulcus" instead of having the complete tridimensional shape of a natural navel. Our results showed great improvement after Donnabella<sup>8</sup> called our attention to the need for

reconstructing all three anatomical landmarks (i.e., base, grooving, and ring) to aesthetically enhance the new umbilicus. In his publication in 2013, he described two internal and absorbable stitches grasping the dermis of both flaps into the rectus aponeurosis, assembling the umbilical base.<sup>8</sup> Because the fascia level was the lowest possible level for replacing the new base, he suggested adding two additional absorbable stitches approximating lateral fat into the midline, immediately under and above the retracted base to provide the ideal grooving effect (deepening). The rounded edges of the skin flaps and the tridimensional accommodation of all tissues after final closure naturally resemble the umbilical ring to the anterior abdominal surface.

Strictly following those general concepts, we started to perform a different type of suture to the skin flaps, to make it easier and more accurate for reconstructing the umbilical base, in a standard reproducible way. The dermoaponeurotic looping suture makes it simple to accomplish the desired



**Fig. 6.** Inner scar umbilicus: different final shapes, with normal anatomical landmarks.

effect of squeezing the flaps against each other into the deep aponeurosis, in a most predictable maneuver.<sup>20</sup> We also prefer to use monofilament nylon sutures, which will be later removed, to avoid subcutaneous inflammatory reactions at the thin skin base. We found that maintaining loose external stitches, and tightening them only after completing all the looping passes, not only facilitates the maneuvers but also makes them much more accurate and predictable than internal dermoaponeurotic suturing.

It is known that, despite the technique always being the same, the resulting umbilical shapes may vary, even though the mentioned anatomical landmarks are kept (Fig. 6). Skin quality, subcutaneous thickness, and scar retraction are some of the variables that may influence the final navel aspect, just as occurs in nature, where several different umbilical shapes might develop to be considered normal, both in men and in women. The lack of external scarring and the inner healing pattern of the new umbilicus also seem to help establish a better scar quality for both superior and inferior abdominal vertical scars. Our series shows that local complications such as widening and stenosis are unlikely with this technique, and the results are natural and sustainable. Our detailed and standardized description of the looping suture for umbilical reconstruction in vertical abdominoplasty may contribute to designing further investigations, including patient satisfaction surveys, to compare clinical outcomes and aesthetic results of previous techniques.

Routinely building a new inner scar umbilicus in fleur-de-lis abdominoplasty has completely changed our critical view of anterior vertical scars, reducing limitations and expanding indications for the procedure. Such predictable and harmonious lower/central body results allow us to explore new aesthetic horizons, offering patients the great benefits of waist definition and vertical tissue tightening, especially for the massive weight loss population.

## CONCLUSIONS

The inner scar umbilicus is a simple, safe, and reproducible technique, presenting low complication rates, with sustainable, nice, and natural results. The high quality of navel tridimensional reconstruction makes it our first choice for vertical

abdominoplasty and favors its indication, especially for post-bariatric surgery body contouring.

**Flavio H. Mendes, M.D., Ph.D.**

160 Rua Tomaz Antonio Gonzaga  
Lins, Sao Paulo 16400-465, Brazil  
mendesmd@fhmendes.com.br

## REFERENCES

1. Mendes FH, Viterbo F. Abdominoplasty after massive weight loss. In: Avelar JM, ed. *New Concepts on Abdominoplasties and Further Applications*. New York: Springer; 2016:356–388.
2. Franco D, Medeiros J, Farias C, Franco T. Umbilical reconstruction for patients with a midline scar. *Aesthetic Plast Surg*. 2006;30:595–598.
3. Silva FN, Oliveira EA. Neo-omphalloplasty in vertical abdominoplasty. *Rev Bras Cir Plast*. 2010;25:330–336.
4. Reno AB, Mizukami A, Calaes IL, et al. Neo-omphalloplasty in anchor-line abdominoplasty performed in patients who have previously undergone bariatric surgery. *Rev Bras Cir Plast*. 2013;28:114–118.
5. Cavalcante ELF. Neo-umbilicoplasty as an option in umbilical reconstruction in abdominal anchor dermolipectomy post gastroplasty. *Rev Bras Cir Plast*. 2010;25:509–518.
6. Monte ALR. Treatment of the umbilical stenosis in a vertical dermolipectomy patient. *Rev Bras Cir Plast*. 2011;26:167–170.
7. Mizukami A, Ribeiro BB, Reno BA, et al. Retrospective analysis of 70 patients who underwent post-bariatric abdominoplasty with neo-omphalloplasty. *Rev Bras Cir Plast*. 2014;29:89–93.
8. Donnabella A. Anatomical reconstruction of the umbilicus. *Rev Bras Cir Plast*. 2013;28:119–123.
9. Mendes FH, Viterbo F. Defining weight stability for post bariatric body contouring procedures. *Aesthetic Plast Surg*. 2017;41:979–980.
10. Baroudi R. Umbilicoplasty. *Clin Plast Surg*. 1975;2:431–448.
11. Juri J, Juri C, Raiden G. Reconstruction of the umbilicus in abdominoplasty. *Plast Reconstr Surg*. 1979;63:580–582.
12. Malic CC, Spyrou GE, Hough M, Fourie L. Patient satisfaction with two different methods of umbilicoplasty. *Plast Reconstr Surg*. 2007;119:357–361.
13. Craig SB, Faller MS, Puckett CL. In search of the ideal female umbilicus. *Plast Reconstr Surg*. 2000;105:389–392.
14. Rohrich RJ, Sorokin ES, Brown SA, Gibby DL. Is the umbilicus truly midline? Clinical and medicolegal implications. *Plast Reconstr Surg*. 2003;112:259–263; discussion 264–265.
15. Illouz YG. A new safe and aesthetic approach to suction abdominoplasty. *Aesthetic Plast Surg*. 1992;16:237–245.
16. Clo TCT. Neo-omphalloplasty using an X-shaped incision in 401 consecutive abdominoplasties. *Rev Bras Cir Plast*. 2013;28:375–380.
17. Nogueira DSC. Routine neo-omphalloplasty during abdominoplasties. *Rev Bras Cir Plast*. 2008;23:207–213.
18. Freitas JOG, Guerreiro V, Sperli, AE. Neoonphalloplasty in abdominal dermolipectomy: Double “V” technique. *Rev Bras Cir Plast*. 2010;25:504–508.
19. Abreu Ng JA. Abdominoplasty: Neoomphalloplasty without scar or fat excision. *Rev Bras Cir Plast*. 2010;25:499–503.
20. Mendes FH, Viterbo F, eds. *Cirurgia Plástica Pós Bariátrica*. Rio de Janeiro: DiLivros; 2016.